



Radiographic Assessment of Anatomy of Nasopalatine Canal for Dental Implant Placement: A Cone Beam Computed Tomographic Study

¹Jaligama B Rao, ²Pramod Tatuskar, ³Ashwini Pulla, ⁴Naveen Kumar, ⁵Swati C Patil, ⁶Ila Tiwari

ABSTRACT

Aim: The aim of this study is to assess the morphology of nasopalatine canal (NPC) with cone beam computed tomography (CBCT).

Materials and methods: A total of 460 subjects of both genders were subjected to CBCT with NewTom machine, and sagittal and coronal sections were used for evaluation of the shape of NPC and width of buccal cortical plate. Types of NPC were also assessed.

Results: Of 460 subjects, males were 210 and females were 250. The difference was nonsignificant ($p = 0.1$). Type III canals were mostly seen in both males and females, followed by types I and II. The mean length of NPC in males and females showed statistical significant difference ($p < 0.05$). Males showed significantly higher diameter of nasal opening, oral opening, and width of the buccal bone plate over the oral opening as compared with females.

Conclusion: The exact location, morphology, and dimensions of NPC can be well visualized with CBCT. All findings were higher in males as compared with females.

Clinical significance: The success of dental implant in maxillary anterior region may be affected by the approximation with NPC. The exact location and morphology play an important role for the correct placement of implant. Cone beam computed tomography is a useful tool providing three-dimensional images in all sections.

Keywords: Cone beam computed tomography, Dental implant, Nasopalatine canal.

How to cite this article: Rao JB, Tatuskar P, Pulla A, Kumar N, Patil SC, Tiwari I. Radiographic Assessment of Anatomy of Nasopalatine Canal for Dental Implant Placement: A Cone Beam Computed Tomographic Study. *J Contemp Dent Pract* 2018;19(3):1-5.

Source of support: Nil

Conflict of interest: None

INTRODUCTION

Esthetics is a prime factor for people. It becomes crucial when it is related to teeth. Natural teeth add beatification to the face. Any lost teeth needs to be replaced. Earlier, missing teeth were replaced by removable partial denture (RPD) followed by fixed partial denture (FPD). Both carry its disadvantages.¹ Patients feel difficult in wearing RPD due to the presence of clasps which may impinge into the soft tissue leading to local trauma. This shortcoming has been replaced by FPD though, for one missing tooth, the tooth anterior and posterior to it requires cutting. This is the biggest drawback with FPD, and moreover, sensitivity of abutment teeth after crown reduction plays an important role in decreasing trend of FPDs among patients.²

Dental implant has emerged as new treatment modality for edentulous areas. Nowadays, dental implants are considered as the method of choice for replacing missing teeth. It has ability to restore the functional and esthetic need of patients. The placement of implant provides benefit to the patient as it provides good esthetic results

¹Department of Oral and Maxillofacial Surgery, Kamineni Institute of Dental Sciences, Nalgonda, Telangana, India

²Department of Periodontics, College of Dental Sciences Davangere, Karnataka, India

³Department of Periodontics, Kamineni Institute of Dental Sciences, Nalgonda, Telangana, India

⁴Department of Prosthodontics, CKS Theja Institute of Dental Sciences and Research, Tirupati, Andhra Pradesh, India

⁵Department of Oral and Maxillofacial Surgery, Triveni Institute of Dental Sciences, Hospital & Research Center, Bilaspur Chhattisgarh, India

⁶Department of Periodontics, Triveni Institute of Dental Sciences Hospital & Research Center, Bilaspur, Chhattisgarh, India

Corresponding Author: Jaligama B Rao, Department of Oral and Maxillofacial Surgery, Kamineni Institute of Dental Sciences Nalgonda, Telangana, India, Phone: +919246558551, e-mail: drjbrahmjirao@gmail.com

with no crown preparation as is done in case of FPD. Although it has become the treatment of choice for most of the dentists, still the complications arising from dental implant placement are the biggest challenge.³

Maxillary anterior teeth are more prone to fracture in children and are considered to be esthetically important teeth. The success rate of dental implant in maxillary anterior region depends on location and angle of implant. The adequate distance between implant and anatomical structures is the foremost requirement. The NPC is a bony connection between the nasal and oral cavities and contains relative neurovascular bundle. The thorough knowledge about the anatomical variations of the NPC is fundamental for avoiding neurovascular bundle damage.⁴

Earlier, the implant site was assessed with the help of two-dimensional (2D) imaging modality, such as intraoral periapical radiograph and panoramic radiographs. Since these imaging modalities are 2D, there are restrictions of implant planning leading to implant failures.⁵ With the advent of CBCT, this limitation has been overcome. Cone-beam computed tomography provides all three dimensions and has been proved as tool to radiology, especially in the success of implant. It provides high spatial resolution and offers less patient exposure as compared with full-mouth radiographs and CT. Cone beam computed tomography images become essential when there is the proximity of area to vital structures.⁶ The present study was conducted to determine the variation in morphology of NPC with the help of CBCT images.

MATERIALS AND METHODS

This study was conducted on 460 patients. All were informed about the study, and written consent was obtained. Ethical clearance was taken from the institutional ethical committee. Inclusion criteria were patients above 18 years of age. However, patients with cleft lip/palate, impacted teeth, and any pathology of NPC were excluded from the study.

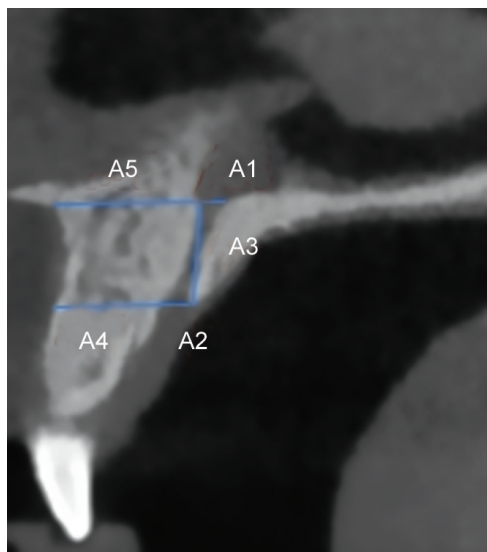
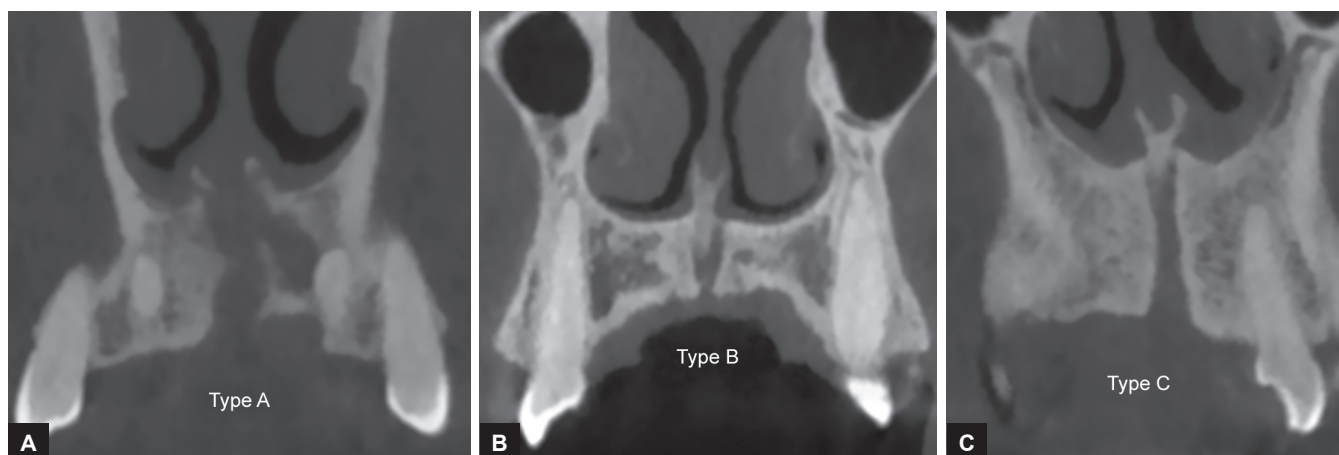


Fig. 1: Sagittal sections of CBCT images showing NPC

All were subjected to CBCT using NewTom machine with the field of view of 11 cm × 8 cm and resolution of 0.3 mm × 0.3 mm × 0.3 mm operating at 120 kVp at 5 mA. The NNT software with slice thickness of 0.1 mm was used in this study. All CBCT images were assessed for NPC dimensions (sagittal sections) and anatomy (coronal sections). The analysis was performed by expert radiologist. Sagittal sections of CBCT images were used for the measurements of dimensions of the NPC. Following measurements were carried out: A1—diameter of nasal opening, A2—diameter of oral opening, A3—length of the canal, A4—width of the buccal bone plate over the oral opening, and A5—width of the buccal bone plate over the nasal opening (Fig. 1).

Nasopalatine canal anatomy was grouped into three types based on Bornstein et al⁷ classification. Type I shows single canal, type II with two parallel canals, and type III includes variations of the Y-type of canal with one oral opening (incisive foramen) and two or more nasal openings (foramina of Stensen; Fig. 2).

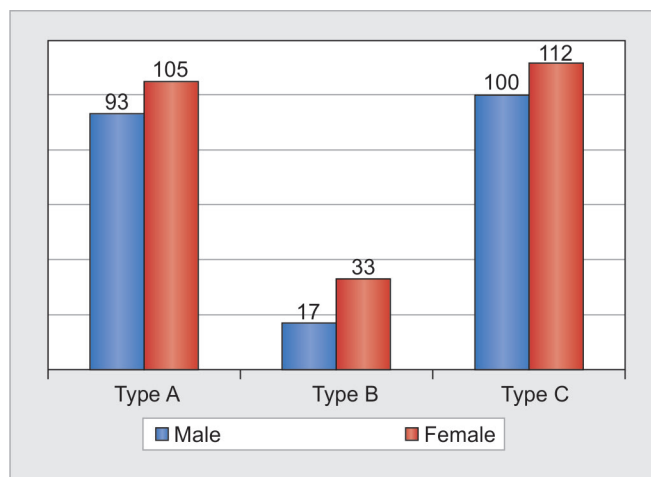


Figs 2A to C: The CBCT images show types of NPC

Student's t-test was used to compare the mean of dimensions. Chi-square test was used to compare the frequency of canal shapes. Statistical Package for the Social Sciences (SPSS) version 17.0 (SPSS, Inc., Chicago, Illinois, USA) was used for data analysis.

RESULTS

Table 1 shows that of 460 subjects, males were 210 and females were 250. The difference was statistically non-significant ($p = 0.1$). Table 2 presents that mean \pm standard deviation (SD) diameter of nasal opening (A1) of NPC was 3.16 ± 1.48 , diameter of oral opening (A2) of NPC was 3.16 ± 1.012 , length of the canal (A3) was 10.32 ± 2.70 , width of the buccal bone plate over the oral opening (A4) was 7.06 ± 1.40 , and width of the buccal bone plate over the nasal opening (A5) was 8.44 ± 2.14 . Graph 1 shows that males showed predominantly type III (100), type I (93), and type II (17) morphologies of NPC. Females had predominantly type III (112), type I (105), and type II (33) morphologies. The difference was statistically non-significant ($p > 0.05$). Table 3 summarizes the effect of gender on measured dimensions of NPC. It was found that A1, A2, A3, and A4 were significantly higher in males as compared with females. However, A5 was non-significant



Graph 1: Types of nasopalatine canal

in both genders. Table 4 shows the width of the buccal cortical bone and dimension in different forms of NPC. The measured dimensions in different types of canal did not show statistical significant difference. The A1 dimension showed statistical significant difference ($p < 0.05$).

DISCUSSION

Maxillary anterior teeth play an important role in the development of esthetics of an individual. These teeth are more vulnerable to get fractured. With the advent of implants in dentistry, the replacement of missing maxillary anterior teeth has become easy. It has nowadays preferable choice of patients also. For the placement of dental implant in anterior region, the exact location and morphology of NPC are the foremost requirements.⁸ Several previous studies have studied the pathology in regard to NPC region, but the anatomical disparity in the dimensions and morphology of NPC remain poorly acknowledged. The present study was conducted to determine the morphology of NPC.

Song et al⁹ have demonstrated that the length of the NPC is 12.0 mm (8.4–15.8 mm) in dentulous maxillae, and

Table 1: Distribution of subjects

Gender	n	p-value
Males	210	0.1
Females	250	
Total	460	

Table 2: Measured dimensions on sagittal images

Variable	Maximum	Minimum	Mean \pm SD
A1 (mm)	11.00	0.4	3.16 ± 1.48
A2 (mm)	6.02	1.03	3.16 ± 1.012
A3 (mm)	22.00	6.00	10.32 ± 2.70
A4 (mm)	13.00	3.00	7.06 ± 1.40
A5 (mm)	15.00	1.04	8.44 ± 2.14

Table 3: Effect of gender on measured dimensions

Gender	Dimension measurements (mean \pm SD)				
	A1	A2	A3	A4	A5
Male	3.38 ± 1.52	3.40 ± 1.02	11.40 ± 2.52	7.40 ± 1.32	8.50 ± 2.02
Female	2.90 ± 1.42	2.98 ± 1.00	9.38 ± 2.44	6.84 ± 1.22	8.54 ± 2.05
p-value	0.01	0.001	0.001	0.03	0.658

Table 4: Comparison of NPC and buccal cortical plate dimension

Canals	A1	A2	A3	A4	A5
A	2.90 ± 1.22	3.18 ± 0.92	10.58 ± 2.95	7.12 ± 1.52	8.18 ± 2.40
B	3.78 ± 2.12	3.10 ± 1.02	10.48 ± 2.90	7.38 ± 1.62	8.68 ± 1.92
C	3.27 ± 1.63	3.24 ± 1.92	10.11 ± 2.57	6.95 ± 1.28	8.58 ± 1.87
p-value	0.001	0.54	0.28	0.31	0.42

Mraiwa et al¹⁰ have reported a mean length of 8.1 ± 3.4 mm. In our study, we included 460 patients of both genders. The mean length of NPC was 11.40 ± 2.52 mm in males and 9.38 ± 2.44 mm in females. Males showed significantly more length as compared with females. Our results are in agreement with Safi et al¹¹. We found the effect of gender on measured dimensions of NPC. It was found that diameter of nasal opening (A1), oral opening (A2), and width of the buccal bone plate over the oral opening (A4) were significantly higher in males as compared with females. This is in agreement with Acar and Kamburoğlu.¹²

Albeit, a recent study conducted by Nasseh et al¹³ observed that the form of the NPC is variable: predominantly cylindrical or funnel shaped. For the canal length, the inclination related to the hard palate, and the incisive foramen anteroposterior diameter, no statistical significance between genders was observed except for the canal height that was found shorter in females.

Kajan et al¹⁴ in their study on Iranian population found that mean values for oral and nasal opening of NPC were 3.53 ± 1.01 and 3.7 ± 2.3 mm respectively, whereas in the present study, it was 3.38 ± 1.52 and 3.40 ± 1.02 mm in males and 2.90 ± 1.42 and 2.98 ± 1.00 mm in females. In our study, we found that type III canals were higher in both males and females as compared with types I and II. Similar findings were seen in a study by Güncü et al¹⁵ who found type III canals in 46.5% of study population. Thakur et al¹⁶ did not reveal statistically significant differences in the number of openings at the nasal fossa, diameter of the nasal fossa openings, and diameter of the incisive fossa.

We evaluated width of buccal cortical bone in different forms of NPC. There was no statistically significant difference in different canals. Bronstein et al¹⁷ in their study found that buccal bone plate is affected by gender.

Fernández-Alonso et al¹⁸ also commented that the presence or absence of maxillary anterior teeth also affects the dimension of buccal cortical plate. However, in our study, we included all dentate patients with the presence of maxillary incisors.

The shape, curvature, and angulation of the canal and its anteroposterior dimensions are the imperative factors for placement of implants in the maxillary incisor region. In addition to this, the number of openings, length of the canal, mediolateral dimensions, and level of its division may prove to be a significant parameter when implants within the NPC are being considered. In dental status, the periodontal condition of remaining central incisors should also be evaluated when the bone level and NPC dimensions are assessed.

Peñarrocha et al¹⁹ conducted a study on 13 patients having atrophic edentulous maxillae with a mean age of 54.8 years, which includes 5 males and 8 females.

Seventy-eight implants were placed: 13 in the NPC, 12 in the pterygomaxillary region, 6 in the zygomatic bone, 2 in the frontomaxillary buttress, and 45 in other locations. A reduced sensitivity was noted in six patients in the anterior palate after surgery, which resolute in all cases within a few weeks. Two nasopalatine implant failures were observed before prosthesis placement, and no failures were recorded after prosthetic loading of implants. A high success rate of 84.6% was observed after an average follow-up of 2 years. They inferred that NPC can be considered as a possible site for an anterior implant placement when restoring atrophic patients using implant-supported prostheses.

Cone beam computed tomography has revolutionarily changed the dental implant success rate. The complexity of NPC can be well visualized by the three-dimensional imaging modality, such as CBCT. It has the advantage of providing fine details in all three sections, such as sagittal, coronal, and axial. Thus, the placement of dental implant in maxillary anterior region is no more a complex procedure.¹

CONCLUSION

The exact morphology and shape of NPC can be determined with the help of CBCT images. All three sections, especially sagittal and coronal views, provide useful information. Morphology and anatomy of nasopalatine canal can be considered as an important parameter when implants within the NPC are being considered.

CLINICAL SIGNIFICANCE

The limitation of 2D imaging has been overcome by the advent of CBCT. With this imaging technique, the exact approximation of anatomical structure from dental implant can be determined, thus ensuring the success of treatment modality.

REFERENCES

1. Schwartz-Arad D, Levin L, Ashkenazi M. Treatment options of untreatable traumatized anteriormaxillary teeth for future use of dental implantation. *Implant Dent* 2004 Jun;13(2):120-128.
2. Teughels W, Merheb J, Quiryren M. Critical horizontal dimensions of interproximal and buccal bone around implants for optimal aesthetic outcomes: a systematic review. *Clin Oral Implants Res* 2009 Sep;20(Suppl 4):134-145.
3. Artzi Z, Nemcovsky CE, Bitlitum I, Segal P. Displacement of the incisive foramen in conjunction with implant placement in the anterior maxilla without jeopardizing vitality of nasopalatine nerve and vessels: a novel surgical approach. *Clin Oral Implants Res* 2000 Oct;11(5):505-510.
4. Chatriyanuyoke P, Lu CI, Suzuki Y, Lozada JL, Rungcharassaeng K, Kan JY, Goodacre CJ. Nasopalatine canal position relative to the maxillary central incisors: a cone beam computed tomography assessment. *J Oral Implantol* 2012 Dec;38(6):713-717.

5. Shiratori LN, Marotti J, Yamanouchi J, Chilvarquer I, Contin I, Tortamano-Neto P. Measurement of buccal bone volume of dental implants by means of cone-beam computed tomography. *Clin Oral Implants Res* 2012 Jul;23(7):797-804.
6. López Jornet P, Boix P, Sanchez Perez A, Boracchia A. Morphological characterization of the anterior palatine region using cone beam computed tomography. *Clin Implant Dent Relat Res* 2015 Oct;17(Suppl 2):e459-e464.
7. Bornstein MM, Balsiger R, Sendi P, von Arx T. Morphology of the nasopalatine canal and dental implant surgery: a radiographic analysis of 100 consecutive patients using limited cone-beam computed tomography. *Clin Oral Implants Res* 2011 Mar;22(3):295-301.
8. Etoz M, Sisman Y. Evaluation of the nasopalatine canal and variations with cone-beam computed tomography. *Surg Radiol Anat* 2014 Oct;36(8):805-812.
9. Song WC, Jo DI, Lee JY, Kim JN, Hur MS, Hu KS, Kim HJ, Shin C, Koh KS. Microanatomy of the incisive canal using three-dimensional reconstruction of micro CT images: an *ex vivo* study. *Oral Surg Oral Med Oral Pathol Oral Radiol Endod* 2009 Oct;108(4):583-590.
10. Mraiwa N, Jacobs R, Van Cleynenbreugel J, Sanderink G, Schutyser F, Suetens P, van Steenberghe D, Quirynen M. The nasopalatine canal revisited using 2D and 3D CT imaging. *Dentomaxillofac Radiol* 2004 Nov;33(6):396-402.
11. Safi Y, Moshfeghi M, Rahimian S, Kheirkhahi M, Manouchehri ME. Assessment of Nasopalatine canal anatomic variations using cone beam computed tomography in a group of Iranian population. *Iran J Radiol* 2017 Jan;14(1):e37028.
12. Acar B, Kamburoğlu K. Morphological and volumetric evaluation of the nasopalatine canal in a Turkish population using cone-beam computed tomography. *Surg Radiol Anat* 2015 Apr;37(3):259-265.
13. Nasseh I, Aoun G, Sokhn S. Assessment of the nasopalatine canal: an anatomical study. *Acta Inform Med* 2017 Mar;25(1):34-38.
14. Kajan ZD, Kia J, Motevasseli S, Rezaian SR. Evaluation of the nasopalatine canal with cone-beam computed tomography in an Iranian population. *Dent Res J (Isfahan)* 2015 Jan-Feb;12(1):14-19.
15. Güncü GN, Yıldırım YD, Yılmaz HG, Galindo-Moreno P, Velasco-Torres M, Al-Hezaimi K, Al-Shawaf R, Karabulut E, Wang HL, Tözüm TF. Is there a gender difference in anatomic features of incisive canal and maxillary environmental bone? *Clin Oral Implants Res* 2013 Sep;24(9):1023-1026.
16. Thakur AR, Burde K, Guttal K, Naikmasur VG. Anatomy and morphology of the nasopalatine canal using cone-beam computed tomography. *Imaging Sci Dent* 2013 Dec;43(4):273-281.
18. Fernández-Alonso A, Suárez-Quintanilla JA, Muínelo-Lorenzo J, Bornstein MM, Blanco-Carrión A, Suárez-Cunqueiro MM. Three-dimensional study of nasopalatine canal morphology: a descriptive retrospective analysis using cone-beam computed tomography. *Surg Radiol Anat* 2014 Nov;36(9):895-905.
19. Peñarrocha D, Candel E, Guirado JL, Canullo L, Peñarrocha M. Implants placed in the nasopalatine canal to rehabilitate severely atrophic maxillae: a retrospective study with long follow-up. *J Oral Implantol* 2014 Dec;40(6):699-706.